

Patellar fractures fixation using cannulated screws and fiber wire tension band

Emad Eldin Essmat¹, MD; Elsayed M Bayomy², MD and Mohamed yousry shaheen³, MBBCh

1- Professor Department of Orthopedic Surgery; Benha University, Egypt.

2- Assistant professor Department of Orthopedic Surgery; Benha University, Egypt.

3- MBBCh Faculty of Medicine; Benha University, Egypt.

Correspondence author: Mohamed yousry shaheen, MBBCh

Address : benha

Tel. : +20 109 707 5868

e-mail: mohamedyousry1993@gmail.com

The Egyptian Orthopedic Journal;

Abstract

Purpose

This study aims to evaluate the results of Patellar fractures fixation using cannulated screws and fiber wire tension band.

Patients and Methods

A prospective study was held in Benha university hospital including 30 patients with transverse patellar fractures fixed with cannulated screws with fiber wire tension band.. All the patients were followed up for a minimum period of 12 weeks and the maximum period of follow up was 24 weeks. Post operatively, these patients were assessed clinically by Levack's score. Fracture union was confirmed radiological. All patients were evaluated and assessed using the questionnaires at 3, 6 months after surgery. Subjective evaluation consisted of recording pain using (visual analogue scale) with Categorization of pain to five levels: none, mild, moderate, severe, unbearable.

Results

The mean age of the studied patients was 32 ±9 years, and there was a male predominance (70%). More than half of the patients had right-sided affection (56.7%). The mechanisms of injury were direct(30%), falling(46.6%), or RTA(23.3%).the affected side was the right side in (56.7%)and left side in (43.3%). The median time from injury was 3 days, and it ranged from 1 to 6 days. The mean time of surgery was 41 ±18 minutes. All patients showed radiological union at 8 weeks, passive ROM at 4 weeks, active ROM at 6 weeks, start of weight-bearing as tolerated within brace at 4 weeks, and start of weight-bearing & ROM without restrictions at 8 weeks At the final follow-up At 3 months, the median total levacks score was 12, and it ranged from 9 to 12. At six months, the median was 12, and the range significantly increased (11 – 12) (P < 0.001). The reported complications were skin infection (13.3%), stiffness (6.7%), and mild pain (53.3%).

Conclusion

The cannulated screws with fiber wire tension band technique is a successful efficient treatment of transverse patellar fractures.

Keywords

Patellar fractures, fiber wire tension band and cannulated screws.

Introduction

Patellar fractures constitute only 1% of all injuries of the human skeleton only approximately one-third requires surgical interventions. Most fractures occur between the ages of 30 to 60 years. Surgical intervention becomes necessary either when the fracture gap exceeds 2-3mm or in case of joint incongruence or if failed extensor mechanism. ⁽¹⁾

Fractures of the patella may result from either direct or indirect mechanisms. ⁽²⁾

As the patella is an essential component of a fully functional knee. The overall underlying surgical treatment is to anatomically reduce the articulating surfaces while subsequently stabilizing it. Reconstruction of the extensor function and early mobilization also constitute the key objectives in surgical intervention. ^(3, 4, 5)

The principle of the tension band technique is to convert the tension forces acting on the anterior surface into compression forces at the articular

surface. ^(6, 7)

Combining interfragmentary screw fixation with the tension band principle appears to provide improved stability over the modified tension band or screws alone for transverse patella fractures. Cannulated screws allow simple, reliable addition of a tension band to screw fixation. ⁽⁸⁾

Symptomatic hardware is a frequent complication following open reduction and often requires reoperation for hardware removal. Loss of reduction and nonunion are also known complications contributing to high reoperation rates. Due to these historical complications associated with metal wiring, techniques using alternative materials such as braided synthetic suture have been described. In this article, we describe a technique for patella fracture fixation using cannulated compression screws with synthetic high- strength nonabsorbable sutures

functioning as the tension band (Fiber Wire Cerclage System).⁽¹⁾

Patients and Methods

A prospective study was held in Benha university hospital including 30 patients with transverse patellar fractures fixed with cannulated screws with fiber wire tension band. A written consent was obtained and the patients were informed about the surgical procedure. All the patients were followed up for a minimum period of 12 weeks and the maximum period of follow up was 24 weeks. Post operatively, these patients were assessed clinically by Levack's score. Fracture union was confirmed radiological.

Inclusion criteria were Failed extensor mechanism (patient not able to lift leg straight). Articular displacement >2 mm, or interfragmentary displacement >3 mm [7, 8]. Transverse patellar fractures .Intra-articular fractures. Closed fractures. Open fractures grade I, II and III with no contamination. Exclusion criteria included: Old, neglected fractures with patellofemoral osteoarthritic changes .Concomitant knee injuries. Delayed union or non-united fractures. Open contaminated fractures. Patients who are medically un-fit for operations.

The mean age of the studied patients was 32 ±9 years, and there was a male predominance (70%) More than half of the patients had right-sided affection (56.7%). The mechanisms of injury were direct(30%), falling(46.6%), or RTA(23.3%).

Preoperative Assessments

A complete knee assessment, including history and physical examination, was performed in all patients.

Patient history included identifying the mechanism of injury. knee examination was performed as tolerated by pain , which included inspection , testing the extensor mechanism in the form of straight leg raising. The fractured limb was splinted in above knee posterior slab. All Patients were admitted in the hospital till time of surgery. Standard x-ray anteroposterior (AP), lateral views of knee. Also ct scan Axial, coronal, sagittal and 3d films. One dose of preoperative antibiotics (Ceftriaxone) 1gm Intravenous was given to all patients within 30 min before induction of anesthesia.

Clinical findings were evaluated using Levack's score in terms of discomfort, impairment of movement, quadriceps muscle power, and subjective functional evaluation. Radiographic evaluation included true anteroposterior and axillary views of the shoulder and an MRI of the shoulder was done. All patients will be evaluated and assessed using the questionnaires at 3, 6 months after surgery. Subjective evaluation consisted of recording pain using

(visual analogue scale) with Categorization of pain to five levels: none, mild, moderate, severe, unbearable.

Operative technique

All patients received preoperative antibiotic prophylaxis within 30 minutes before the beginning of the procedure. spinal anesthesia was used in all the patients with supine position. a cushion was used under the ipsilateral hip to avoid external rotation of the leg. An anterior longitudinal midline skin incision over the patella was used which can be extended proximally and distally if needed

evacuation of the fracture hematoma and irrigation of the knee joint .Reduction using reduction forceps (Fig.1).

Anatomical reduction of the articular surface was checked by digital palpation of the patellar articular surface inside the knee through arthrotomy incision and rechecked by fluoroscopy. Two parallel threaded guide pins were placed within the patella (Fig.1). Drilling the fracture fragments over the guide pins was done only for the near cortex. Screws lengths were measured, Two 4.0mm cannulated partially threaded screws were inserted over the guide pins to achieve interfragmentary compression (Fig.2). Fiber wire 5 mm was passed in a figure of eight through the two screws using wide pore cannula and prolene suture passed through the cannulated screws then attached to the fiber wire to guide it through the cannulation of the screws(Fig.3).All threads of the screws passed the fracture site to achieve lag compression effect but not crossing the far cortex to avoid breakage of the fiber wire over the sharp edge of the screw(Fig.4). The fiber wire was tensioned in figure of eight and tightened by twisting both limbs of the wire simultaneously, then knotted securely(Fig.5).Final fluoroscopy image AP/Lateral of patella was checked. Stability was tested by placing the knee from full extension to 90° flexion and checking the patellar tracking. Repairing of medial and lateral retinacula with 0-vicryl. Closure of

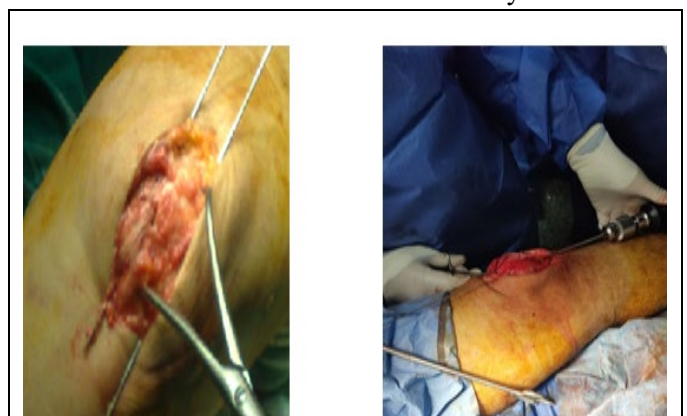


Figure 1:reduction by reduction clamb and inserting two guide wires

the wound was performed in layers, the subcutaneous tissue with 2-0 vicryl and finally, skin closure with 2-0 vicryl, sterile dressing and above knee cast was applied. All the patients were put in above knee back slab.

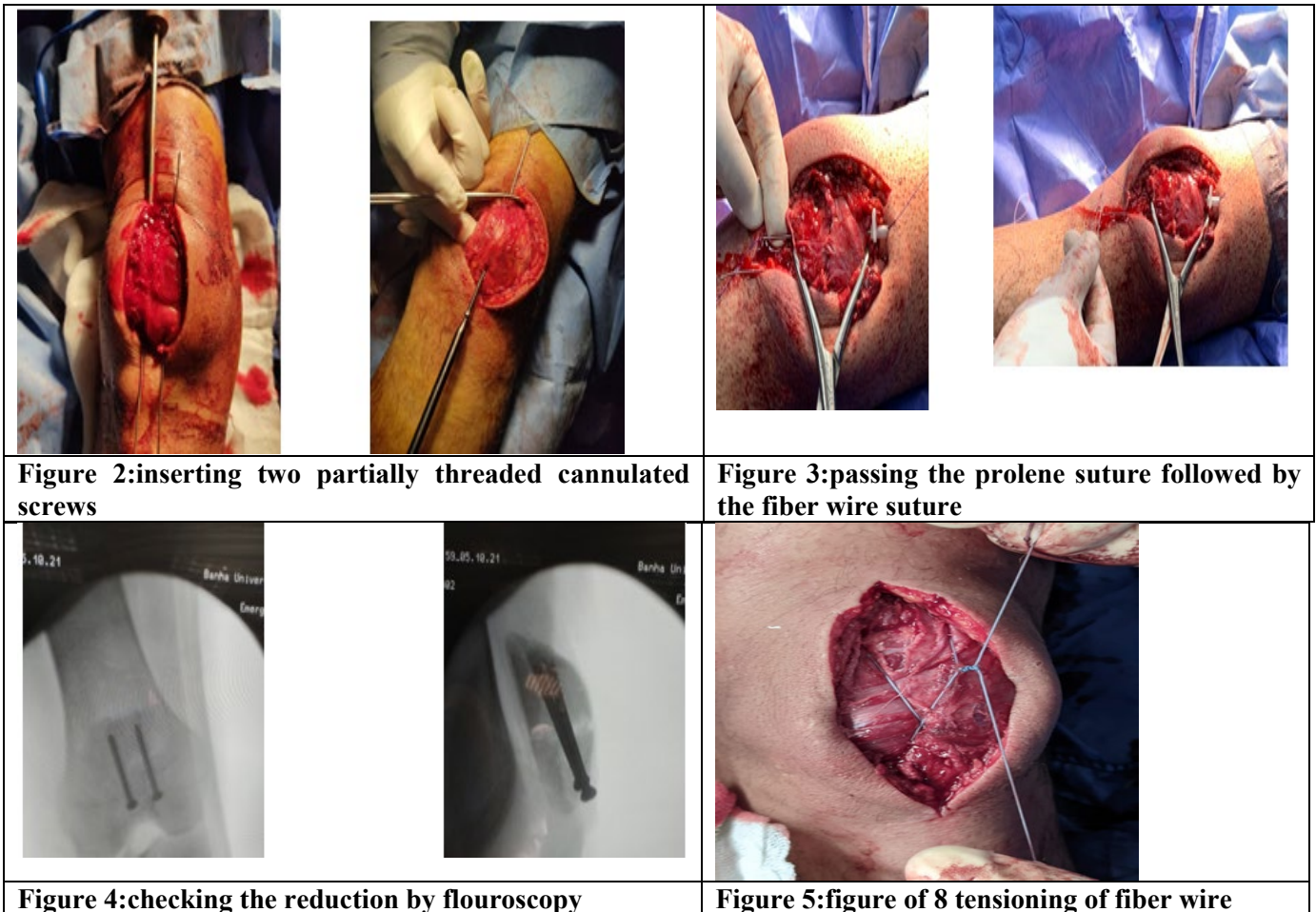


Figure 2:inserting two partially threaded cannulated screws

Figure 3:passing the prolene suture followed by the fiber wire suture

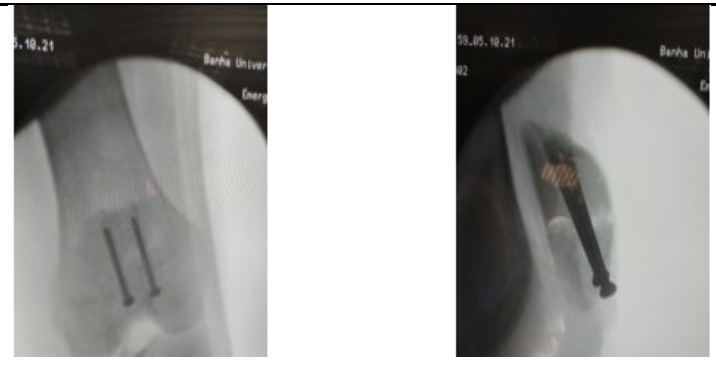


Figure 4:checking the reduction by flouroscopy

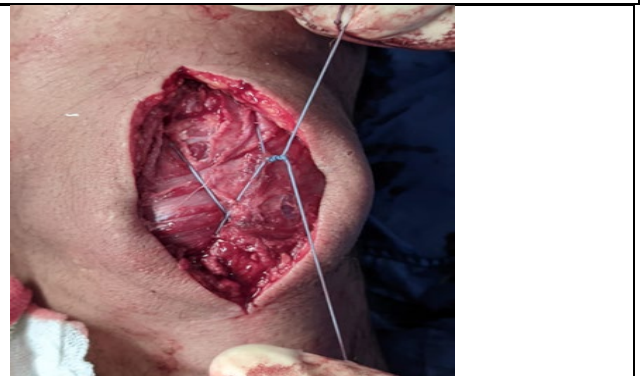


Figure 5:figure of 8 tensioning of fiber wire

postoperative Rehabilitation

Post-operative dose of the antibiotic (ceftriaxone) was given after 12 hours post operatively; Analgesics and anti-edematous medications were prescribed also for all patients. Anti-coagulant dose (rivaroxipan 10mg tab) was given once daily after 12 hours post-operative for 4 weeks. Check x-rays were obtained to assess the reduction post operatively.

Follow up program

all patients were followed up at Benha university hospital outpatient clinic every 2 week following hospital discharge. Serial x-ray radiographs in two planes (A-P and lateral views) were obtained at each visit to ensure maintenance of anatomical reduction and provide basis for the evaluation union.

The stitches were removed after two weeks and the cast was removed after 4 weeks, All patients were advised not to weight bear in the first 4 weeks post operatively.

At **4 weeks** gentle range of motion exercises were started gradually and started weight bearing as tolerated in knee brace locked in extension with crutches if needed.

At **6 weeks** patients were allowed for active ROM and

and continue weight bearing as tolerated.

At **8 weeks** patients achieved full active ROM and full weight bearing without crutches.

Late follow up

All patients will be evaluated and assessed using the questionnaires at 3, 6 months after surgery. Subjective evaluation consisted of recording pain using (visual analogue scale) with Categorization of pain to five levels: none, mild, moderate, severe, unbearable.

Symptoms, signs and subjective assessment	Score
Pain	
No pain	3
Minimal pain during activity	2
Constant severe pain even at rest	1
Limitation of activity	
Unlimited activity	3
Limitation of activities, especially sports	2
Greatly diminished activities	1
Loss of quadriceps power	
No loss of quadriceps strength	3
30%-45% decrease in strength	2
Greater than 45% decrease in strength	1
Subjective functional assessment (%)	
75-100	3
50-74	2
0-49	1

Results

Patient demographic data

The studied group was composed of 21 men and 9 Women. The mean age at the time of surgery was 32 ± 9 years. More than half of the patients had right-sided affection (56.7%).

Injury characteristics

The mechanisms of injury were direct(30%), falling down(46.6%), or RTA(23.3%).

Time to surgery and surgery duration

The median time from injury was 3 days, and it ranged from 1 to 6 days. The mean time of surgery was 41 ± 18 minutes

Outcome

All patients showed radiological union at 8 weeks, passive ROM at 4 weeks, active ROM at 6 weeks, start of weight-bearing as tolerated within brace at 4 weeks, and start of weight-bearing & ROM without restrictions at 8 weeks

Complications

The reported complications were skin infection (13.3%), stiffness (6.7%), and mild pain (53.3%)

Visual analogue score at 6 months

46.7% of patients had no residual pain at the 6th month of follow up, while 53.3% had mild pain with functional limitations.

Levack's score

At 3 months, the median total levacks score was 12, and it ranged from 9 to 12. At six months, the median was 12, and the range significantly increased (11 – 12) ($P < 0.001$)

Discussion

Patellar fractures are relatively uncommon, accounting for one percent of all skeletal injuries. Many patellar fractures, especially transverse fractures, are associated with complete disruption of the extensor mechanism. The objectives of operative treatment are anatomic reduction of the articular surface and restoration of the extensor mechanism while preserving the patella. Internal fixation is used to maintain reduction until the fracture is healed. Early range of motion of the knee will reduce the incidence of postoperative knee stiffness and shorten the disability after patellar fractures. Several different techniques of internal fixation have been employed. Cerclage wiring or wires placed through drill holes were the most commonly used techniques until the introduction of the tension band wiring method by the AO group

Clinically, it can be difficult to secure the tension band wire directly down against the patella, allowing the fragments to slip apart with quadriceps contraction. In addition, patient reports of skin irritation from

prominent hardware are very common postoperatively. ⁽²⁾ Some surgeons have used interfragmentary screws to prevent the fracture from sliding apart and to decrease the frequency of hardware irritation to the surrounding soft tissues. Others have recommended using a tension band in combination with interfragmentary cannulated screws

This prospective randomized study reviewed the results of treatment of 30 patients with transverse patellar fractures at Benha University Hospitals by two cannulated screws with fiber wire tension band. Several comparative studies had been done to evaluate different methods of the treatment of patellar fractures with the same results of this study.

As regard to fixation patella using cannulated screws with tension band wiring, Berg EE. ⁽¹⁰⁾ Managed ten patients with displaced transverse patellar fractures with a tensioned anterior figure of eight wires placed through parallel cannulated screws. They use modified HSS knee scoring system. Seven patients (70%) had excellent and good results while three patients (30%) had fair results.

Hatab et al.⁽¹¹⁾ Twenty patients were treated by open reduction and internal fixation with figure of eight tension band wire through cannulated screws. They used modified HSS knee scoring system. The final results of the study showed fourteen patients (70%) had excellent results, five (25%) good result, one (5%) fair result and no patient had a poor result. With high outcome final result, that support what concluded in this study.

Chengxue ⁽¹²⁾ Seventy two patients were retrospectively among whom 37 patients were fixed by the modified tension band technique and 35 patients were fixed by the titanium cannulated lag screws. The result were better in the titanium cannulated lag screws group (excellent 32 patients (91.4%) ; good 3 (8.6%) ; fair and poor, none) than in the modified tension band group (excellent 21 patients (56.6%) ; good 9 (24.5%) ;fair 6 (16.2%); poor 1(2.7%)), the previous series were almost similar to this study which showed the higher mean score (modified HSS knee score) in cannulated screws with tension band wiring than kirschner wires with tension band wiring.

As regard to fixation fracture patella using Fiber Wire tension band Lawrence Camarda et al (13) in 2016 performed a retrospective study of twenty patients, 17 were available for clinical and radiological follow-up (12 men and 5 women) fixed by Fiber Wire non-absorbable suture was used, and a peripatellar circumferential Cerclage was performed in a purse string fashion close to the bone. Average Bostman scores at 3 months postoperatively and final follow-up were 25.2 ± 2 (range 20–30) and 28.3 ± 1.6 (range 26–30), respectively. Further, the mean Lysholm score at final follow-up was 91 points ± 5.7 (range 83–100). All fractures healed (time to union 9.2 ± 2 weeks) and no fixation failure was observed in the group studied. Slight losses of reduction (4 mm) were noted in two patients at 4 weeks postoperatively.

Tian et al. (6) retrospectively reviewed 101 patients, 52 patients were fixed by the modified tension band group and 49 were fixed by the titanium cable-cannulated Screw tension band group. the result were better ($p = 0.01$) in the titanium cable-cannulated screw tension band group (excellent 45 patients (91.8%) ; good ,four (8.2%); fair and poor, none) than in the modified K-wire tension band group (excellent 36 patients(69.3%) ; good nine(17.3%) ;fair four(7.7%) ;poor three(5.7%)

In this study one patient lost 10 degrees of terminal flexion of the knee and 2 patients lost 20 degrees of terminal flexion of the knee but this did not affect patient satisfaction, no patients were developed any flexion contracture or extensor lag, Hatab et al (11) no patient had a flexion contracture or an extensor lag. three patients loss of terminal flexion , one patient lost 30 degrees, another lost 20 degrees while the last lost 10 degrees, Lawrence Camarda et al (13) No patient had significant flexion contracture. Average ROM was 131.1 for flexion (range 120–140) and 0.5 for extension (range 0–3). No significant ROM differences were noted with the uninjured contralateral knee. Because of noncompliance with the postoperative rehabilitation protocol, one patient presented knee stiffness at 2 months postoperatively that required gentle manipulation under anesthesia.

The previous series were almost similar to this study which showed no patients had developed any flexion contracture or extensor lag but patients had loss of terminal flexion of the knee improved after condensed physiotherapy sessions.

In this study the mean age of patients was 32 ± 9 . Which was less than the mean age in Hatab et al (11) (39.25 years), Tian et al (6) (56.6 years) and Berg EE (10) (63 years), Lawrence Camarda et al (12) Average patient age at injury was 46.6 years (range 20–75) there was no statistically significant relation between age and final score.

In this study 21 males (70.0) and 9 females (30.0), in most studies males were more than females, as males are more active so they are more liable to trauma. There was no statistically significant relation between sex and final score.

In this study, The mechanisms of injury were direct(30%), falling(46.6%), or RTA(23.3%). Berg EE(10) had reported three fractures (30%) occurred from severe trauma , four (40%) had moderate trauma, and three (30%) had mild trauma . in this study, patients were younger than in Berg EE (9), males were more than female and osteoporotic patients were not included, so high-energy trauma was the main mechanism of trauma , Lawrence Camarda et al (13) The main mechanisms of injury were fall from height on hard ground in ten cases (59 %) and road traffic accidents in the remaining seven (41 %).

In this study, none of patients had pain due to irritative

symptoms related to hardware, Tian et al (6), a large number, fifty-two patients were in the modified tension band group five patients experienced skin irritation and 49 were in the titanium cable-cannulated screw tension band group with no patients had skin irritation, in Chengxue et al (11) five patients treated by tension band wiring affected by skin irritation due to kirschner wires prominence and no patients treated by cannulated lag screws had skin irritation, the previous series showed higher irritation with kirschner wires more than cannulated screws.

In this study, four patients had superficial infection improved later on with antibiotics and dressing. Berg EE (10) and Hatab et al (11) included no infection patients, in this study ,the patients were developed just superficial infection were usually occurred in old age patients and all patients effectively treated by parenteral empirical antibiotic , Lawrence Camarda et al (13) The same patient was the only one in the study to require elective FiberWire removal 24 months after surgery. This was performed secondary to a superficial infection, which did not affect the final clinical outcome (ROM 0–125). Another patient underwent knee arthroscopy in another Institution because of anterior knee pain. No patients referred localized pain deriving from prominent suture knots.

Limitation of the current study include the relative small numbers of patients , the lacking of control group , the short follow up time and the wide exclusion criteria. It's recommended that these potential limitations should be taken into account in larger prospective studies that may be conducted in the future with more inclusion criteria.

Conclusion

The cannulated screws with fiber wire tension band technique is a successful efficient treatment of transverse patellar fractures due to the following reasons:

- Strong fixation combining the lag effect of the screws and the tension band of fiber wire reforming distractive forces into compressive forces .
- No hardware irritation
- No need for secondary operation to remove the hardware unlike other traditional methods that necessitate removal due to irritation of the hardware.
- Reproducible

References

1. Posner AD, Hutchinson I, Zimmerman J. Patellar Fracture Fixation With Cannulated Compression Screws and FiberTape Cerclage. *Arthrosc Tech.* 2021 Jun 1;10(6):e1447–53.
2. Patellofemoral pain: epidemiology, pathophysiology, and treatment options - PubMed [Internet]. [cited 2022 Apr 12].

3-Pailo AF, Malavolta EA, Leme A, Santos GD, Mendes MTR, Rezende MU, et al. Patellar fractures: a decade of treatment – part I: Functional analysis. *Acta ortop bras* 2005; 13: 221-4

4-Ong TK, Chee EK, Wong CL, Thevarajan K. Fixation of Comminuted Patellar Fracture with Combined Cerclage and Tension Band Wiring Technique. *Malaysian Orthopaedic Journal* 2008;2:40-2

5-Shrestha B, Bajracharya A, Rajbhandari A, Singh N. Functional Outcome of Modified Tension Band Wiring in Transverse Fracture of Patella. *Journal of GMC-Nepal* 2009;2:22-9

6-Tian Y, Zhou F, Ji H, Zhang Z, Guo Y. Cannulated screw and cable are superior to modified tension band in the treatment of transverse patella fracture. *Clin Orthop Relat Res.* 2011;469(12):3429-35.

7-Fortis AP, Milis Z, Kostopoulos V, Tsantzalis S, Kormas P, Tzinieris N, et al. Experimental investigation of the tension band in fractures of the patella. *Injury.* 2002;33:489– 93.

8- Kai-Lan Hsu, Wei-Lun Chang, Chyun-Yu Yang, Ming-Long Yeh, Chih-Wei Chang, Factors affecting the outcomes of modified tension band wiring techniques in transverse patellar fractures, *Injury*, Volume 48, Issue 12, 2017

9-Sim, Jae-Chun & Ha, Sung-Sik & Hong, Ki-Do & Kim, Tae-Ho & Sung, Min-Chul. Circumferential Wiring Combined with Tension Band Wiring in the Operative Treatment of Patella Fracture. *Journal of the Korean Fracture Society*, 2014

10-Berg EE. Open reduction internal fixation of displaced transverse patella fractures with figure-eight wiring through parallel cannulated compression screws. *Journal of orthopaedic trauma.* 1997 Nov 1;11(8):573-6.

11-Hatab S, Tanagho A, Ansara S. Evaluation of the results of treatment of patellar fractures by cannulated screws with threaded tension band wire. *Bone and joint journal* 2015

12-Chengxue W, Lei T, Baochang Q, Xiangfeng H, Yulong H, Haipeng Z, Yu Tiecheng *Chinese Journal of Traumatology* 2014;17(4):208-13.

13-Camarda L, La Gattuta A, Butera M, Siragusa F, D'Arienzo M. FiberWire tension band for patellar fractures. *Journal of Orthopaedics and Traumatology.* 2016 Mar;17(1):75-80.